

Research Article

Common reproductive problem associated with one humped camel (*Camelus dromedarius*) in West Africa

Bello A^{1*} and Bodinga HA²¹Department of Veterinary Anatomy, Usmanu Danfodiyo University, Sokoto, Nigeria²Department of Veterinary Surgery and Radiology, Usmanu Danfodiyo University, Sokoto, Nigeria

Abstract

The problems of reproduction in the camel are not extensively investigated as in the bovine, caprine and ovine species. There is need to elucidate the problem in detailed in order to overcome the problem of production and genetic multiplication. The information collected on these problems is derived mainly from questioning the camel owners, slaughterhouse material and very limited clinical and farm observations.

Introduction

Camel is a seasonal breeder and their reproduction is different as compared to other livestock as both male and female come into heat during the breeding season [1]. The female camel matures at an age of 3-4 years while males at the age of 4-5 years. During heat period the male emits a black pigment from his pole gland (skin gland) which helps him to attract the females. The male camel has a specialized inflatable diverticulum of the soft palate called as 'gula'. When the animal is angry or displaying this structure protrudes out from the mouth. The 'gula' is extruded when the camel is physically restrained and protrudes temporarily when the animal is chemically restrained [2]. The gestation period in camels is 390 days with average birth weight 35-40 kgs. The adult camel weighs 450-750 kgs.

The incidence of early embryonic death seems to be high in the camel. It was found that twinning occurs in about 0.4% of 491 single births reported by Musa & Abu Sineina, [3]. In the same study two and three corpora lutea were found in 13.65 % and 1.22 % respectively. The reason for these high prenatal losses is still open for more investigation. Yagil, [4] claims that one of the causes of foetal death is the strong inbreeding in the herds [1].

Pregnancy

In camel 99% pregnancy occurs in left horn. The incidence of twin ovulation is 14%. Twin births occur to an extent of only 0.4% when both the ovaries ovulate at the same oestrus.

More Information

*Address for Correspondence: Bello A, Department of Veterinary Anatomy, Usmanu Danfodiyo University, Sokoto, Nigeria, Tel: +234(0)8039687589; +2348124962652; Email: abccrcfge28@gmail.com; abdulrahman.bello@udusok.edu.ng

Submitted: 18 February 2020

Approved: 02 March 2020

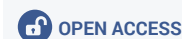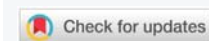
Published: 03 March 2020

How to cite this article: Bello A, Bodinga HA. Common reproductive problem associated with one humped camel (*Camelus dromedarius*) in West Africa. Insights Vet Sci. 2020; 4: 001-003.

DOI: 10.29328/journal.ivs.1001018

Copyright: © 2020 Bello A, et al. This is an open access article distributed under the Creative Commons Attribution License, which permits unrestricted use, distribution, and reproduction in any medium, provided the original work is properly cited.

Keywords: Reproduction Problems; Camelus Dromedarius; West Africa; Pyometra; Endometritis



Embryos develop initially in both horns but, unfortunately one in right horn dies when it reaches a size of 2-3 cms. In camel there is no record of freemartin. The foetal growth is of linear pattern. The posterior presentation predominates (54%-66%) from early pregnancy, in camels. There is no tendency in late pregnancy for the amnion to separate from the allantochorion as it may happen in the cows [1].

Abortion and stillbirth

These are known to occur in camels. The incidence of brucellosis seems to be related to breeding and husbandry practices. In Africa *Brucella melitensis* was found to be the causative agent while in the USSR the infection was found to be due to *Brucella abortus*. The organisms were isolated in the different countries with variable incidence of success. It is claimed that young camels are resistant up to the age of 11 months and that they contract the disease from the dams on subsequent calving. If this is the case, then separation of young camels at 7 to 8 months of age from positive dams might help in the control programme [5].

The role played by brucellosis in the overall picture of abortion in camels is not quantified. It appears that other important endemic diseases play a significant role in the overall incidence of abortion. Trypanosomiasis leading



to general debility and abortion is an important disease. Pasteurellosis and salmonellosis are also considered as causes of abortion in camels. Other causes of abortion include febrile conditions such as pneumonia and camel pox, or nervous excitement [6].

Diseases of the female reproductive tract

Examination of abattoir material provided some information about some of the diseases that could be encountered in the reproductive tract. Although this could be considered as biased information when referring to populations of camels in general, it could however provide useful information about the existence of these diseases. These diseases include: pyometra, bursal and ovarian adhesions, endometritis associated with a partially involuted uterus, and cystic ovarian degeneration [6].

Pyometra: Literally means pus in the womb. It is considered a serious and life threatening condition that must be treated quickly and aggressively. It is secondary infection that occurs as a result of hormonal changes in the female reproductive tract or in some cases a source of ascending infection; meaning it enters the reproductive tract at the vulva from the outside world and creeps up or comes through the blood stream from another infected area of the body. If the camels has also recently given birth, an inflamed wound with bruised or exhausted and vulnerable tissues can also act as a focus for infection to set in. The symptom depends on whether the cervix is open or closed. In case of open cervix, pyometra can present from obvious thick, brownish pus seeping from the camel's (cow) vulva, lethargy, weakness, weight loss and depression, anorexia. While in closed cervix pyometra, the cervix remains tightly closed providing an effective seal capable of withholding the pus and making the condition slightly less obvious to diagnose. Symptoms such as abdominal enlargement, shock and coma could be seen.

Diagnosis is based on history, analysis of vaginal discharge, culture, complete blood count, serum general chemistry profile, urinalysis, x-rays and ultrasound studies.

Treatment of pyometra: Administration of prostaglandin or its analog at normal doses is the treatment of choice. Expulsion of exudate and bacteriologic clearance of the uterus follows in 80% of treated cases. No intrauterine treatment is recommended in conjunction with prostaglandin. Lavage of uterus using large volume of fluid is recommended. Permanent cure in this case requires hysterectomy or wedge resection of cervix to allow continuous uterine drainage. A salvage procedure that allows continuous use of the camel but renders her infertile.

Endometritis associated with partially involuted uterus: Endometritis is inflammation of the uterine lining of the uterus. When the involution is impaired or retarded, it is called sub involution. It is caused by ill maternal health, caesarean section, uterine prolapse, uterine fibroid.

Predisposing factors are: labour, anaesthesia, full bladder, difficult delivery, retained placenta, maternal infection. Signs and symptoms of the condition are, irregular or excessive uterine bleeding, irregular cramp or rise in temperature, uterus feels boggy and softer on palpation.

Treatment of Endometritis: It is by exploration of the uterus in retained product, antibiotics is also recommended.

Cystic ovarian degeneration: Traditionally, cyst have been defined as an ovulatory follicular structure that persist for 10 or more days in the absence of a functional corpus luteum and accompanied by abnormal oestrus behavior (irregular oestrus intervals, nymphomania or anaestrus). Cystic ovarian degeneration is associated with hormonal disturbances. Cystic ovaries were the commonest ovarian lesions. Follicular cyst, haemorrhagic cyst, luteal cyst, dermoid cyst and paraovarian cyst were detected. Symptoms include: intermittent oestrus with exaggerated monosexual drive to bull-like behavior including mounting, pawing the ground and bellowing. This behavior may be accompanied by masculinization of the head and neck.

Treatment of cystic ovarian degeneration: It responds to an LH-type hormonal treatment (HCG). Hormone therapy with GnRH is effective at 100 ug. Prostaglandin and f2 alpha can be given 7 days after HCG or GnRH.

Dystocia

The incidence of camel dystocia appears to be very low [7]. The foetal component of dystocia includes: carpal flexion, lateral deviation of the head and hock and hip flexion. Posterior presentation is uncommon. Foetopelvic disproportion, monstrosities and transverse presentations are rare. On the maternal side, uterine inertia occurs to a small extent. In dealing with dystocia in the camel it was found that head and limb extension is more difficult to achieve than in the cow. However, the camel foetus survives dystocia better than the equine foetus and the camel is a good subject for caesarean section as well as foetotomy.

Embryotomy is possible when necessary. Caesarean section could be performed on the left flank using xylazine sedation and local regional or infiltration anaesthesia [8]. It was documented that a camel that was 17 hours in dystocia, delivered a live foetus by caesarean section [7].

Vaginal prolapse

This is seen clinically in pregnant camels that were well fed with limited exercise. In most of the cases it does not interfere with the pregnancy in question. The condition could be treated successfully by the Bühner technique [7].

Other problems of reproduction

The fertility is defined as the ability of the male and female to produce viable germ cells, mate and conceive and



subsequently give birth to living young [6]. A significant aid to establish precise figures for fertility is record keeping and good management. Unfortunately both are missing under traditional camel raising systems. Existing information indicates that fertility is unlikely to be higher than 50% in pastoral herds and that under improved ranch conditions it could be up to 65% [6].

Poor nutrition and poor grazing are a cause of reduced sexual activity in both females and males. Debilitating diseases such as trypanosomiasis, tuberculosis, mange, pleuropneumonia and heavy parasitism all compromise the fertility rate in the camel. Endocrine factors including insufficient gonadotropins to enhance follicular development and subsequent ovulation may also contribute to fertility rate in camels.

Conclusion and recommendation

Concerning the bacterial flora of the female genitalia in the camel, Zaki & Mousa [9], isolated corynebacteria, micrococci, and gram negative bacilli from the normal genital tract of pregnant and non-pregnant slaughtered animals. Almost the same spectrum of germs was found by Eidarous, et al. [10], however including *E. coli* and *Staph. epidermidis*. According to Nawito, [11], bacteriological findings in the uteri of 2075 one-humped camels of unknown history from the Cairo abattoir was made. In 94 cases (4.53%) clinical symptoms such as abscesses in the uterus, catarrhal endometritis, haemorrhagic endometritis, pyometra and pyometra with macerated foeti were found. *Micrococcus pyogenes* var. *aureus* played the predominant role. Furthermore, *Micrococcus pyogenes* var. *albus*, beta-haemolytic streptococci, *E. coli* and *Pseudomonas aeruginosa* could be isolated from the uteri of animals with clinical symptoms, Nawito, [11].

References

1. Gupta AK, Chowdhary MS, Barket NK. A note on optimum time for service in camel (*Camelus dromedarius*). *Indian J Animal Sci.* 1986; 48: 324-325.
2. Joshi CK, Pareek PK, Vyas KK. Studies on estrous cycle in Bikaneri She-camel. *Indian J Animal Sci.* 1978; 48: 141-145.
3. Musa BE, Abu Sineina ME. Some observations on reproduction in the female camel (*Camelus dromedarius*). *Acta Veterinaria Yugoslavia.* 1976; 26: 63-69.
4. Yagil R. The desert camel: Comparative physiological adaptation (*Comparative animal nutrition*). 1985; 3: 231-236.
5. Higgins A. The camel in health and disease: Reproduction and Genital diseases of camels. *Bailliere Tindall (Publ.)*. 1986; 99: 111-120.
6. Mukasa-Mugerwa E. The camel (*Camelus dromedarius*). A bibliographical review. ILCA Monograph, International Livestock Centre for Africa, Addis Ababa, Ethiopia. 1981.
7. Arthur GH, Noakes DE, Pearson H. *Veterinary reproduction and obstetrics*. 5th Edition. *Bailliere & Tindall (Publ.)*, Eastbourne. 1985; 50-52.
8. Abdulwahhab Al-Juboori, Maher Mohammed Bake. *Camels: Diseases & Treatment*. First Edition. 2003.
9. Zaki K, Mousa A. The bacterial flora of the cervical canal, uterine horn and Fallopian tube in native cows and she-camels. *Fortpfl Haust.* 1965; 1: 229-232.
10. Elidarous A, Mansour H, Abdel-rahim A. Bacterial flora of the genital system of male and female camels. *Zagazig Veterinary J.* 1983.
11. Nawito M. Uterine infection in the camel. *Egypt J Veterinary Sci.* 1973; 10: 17-22.